

Role of Magnetic Resonance Imaging in Staging Rectal Carcinoma

SITARAM BARATH, JEEVAN A VERNEKAR, SACHIN SHASHIKANT AMATE

ABSTRACT

Introduction: Recent advances in management of rectal cancer have led to emphasis on accurate preoperative staging, determination of Circumferential Resection Margin (CRM) and mesorectal fascia involvement. Because of superior soft tissue contrast and multiplanar capability, MRI is currently imaging modality of choice.

Aim: To study imaging characteristics of different rectal tumors. To evaluate accuracy of MRI in local 'T' staging of rectal tumor. Determination of CRM and mesorectal fascia involvement and to evaluate accuracy of MRI in nodal (N) staging.

Materials and Methods: A prospective study of 64 patients presenting with rectal mass/bleeding was conducted in

Department of Radiodiagnosis at tertiary care hospital in Goa (Goa Medical College), over a period of 2 year by using 1.5 Tesla superconductive unit.

Results: Overall accuracy of MRI for 'T' staging was 95.75%, the accuracy was 97.49% for T1 tumor, 94.11% for T2 tumor, 91.66% for T3 tumor and 100% for T4 tumor. MRI was 100% accurate in diagnosing mesorectal fascia invasion.

Conclusion: MRI is currently the only modality that enables accurate evaluation of tumor extent, involvement of CRM and mesorectal fascia. This enables to carefully select those patients who will benefit from neo-adjuvant chemotherapy or primary surgery.

Keywords: Circumferential resection margin, Mesorectal fascia, Rectal adenocarcinoma

INTRODUCTION

Colorectal cancer is the third most common cancer worldwide [1]. Accurate preoperative diagnostic and staging of rectal carcinoma is essential for treatment planning and prognosis. This can be achieved with both endorectal ultrasound (USG) and computed tomography (CT) scan. The most important anatomical landmark for the evaluation of local tumor extent of carcinoma rectum is mesorectal fascia [2]. MRI because of its multiplanar capability and superior soft tissue contrast is currently modality of choice to depict mesorectal fascia and its relation to tumor margin. The other advantage of MRI is lack of ionizing radiation and nephrotoxicity from iodinated contrast material. This study emphasize on role of MRI and its significance for planning an effective therapeutic strategy for the individual patient and also to study imaging characteristics of different histological type of rectal tumor.

MATERIALS AND METHODS

The prospective hospital based study was carried out on 64 cases in Department of Radiology, Goa Medical College and hospital from October 2010 to October 2012, over a period

of 2 years.

Inclusion Criteria: 1) Rectal mass on per rectal examination; 2) Rectal mass on colonoscopy; 3) Biopsy proven carcinoma rectum.

Exclusion Criteria: 1) Patients with cardiac pacemaker in situ; 2) Patients with pelvic metallic implants.

Ethical Clearance for the study was obtained before commencement of the study from Institutional Ethics Committee, Goa Medical College, Bambolim Goa. All patients underwent routine clinical, histopathological and radiological workup. Every patient was given a cleansing enema one hour before the MRI. Informed consent of patient/attendant was taken. The MRI was performed without distending rectum except in patients with smaller lesions which was difficult to characterize. Ultrasound gel was used as a distending agent. Intramuscular injection of Buscopan 20mg was given just prior to the procedure.

MRI performed on 1.5 Tesla (Siemens MAGNETOM Avanto) imaging system with an external body array coil. The following sequences were used:

- 1) T2-weighted turbo spin echo sequences in axial, sagittal and coronal planes for imaging of rectum and mesorectum.
- 2) T1-weighted fat saturated spin echo sequence in axial plane to image for pelvic adenopathy.
- 3) Diffusion weighted imaging in 3 directions in axial plane using the inhouse software.
- 4) HASTE weighted sequence in axial and coronal plane and TRUFI weighted sequence in coronal plane was used with breath hold for screening of upper abdomen.

Interpretation: The findings were recorded in terms of character of tumor on T2WI and diffusion, location of tumor (lower rectum, mid or upper rectum). The 'T' staging of tumor was determined according to AJCC guidelines. The N staging was determined according to AJCC guidelines. The mean Apparent Diffusion Coefficient (ADC) value of the tumor was recorded. Distant metastasis and non regional lymph nodes were also recorded using axial and coronal HASTE weighted images.

American Joint Committee on Cancer: Colon and Rectum Cancer staging [3]:

Primary Tumor (T)

Tx Primary tumor cannot be assessed

T0 No evidence of primary tumor

Tis Carcinoma insitu: intraepithelial or invasion of lamina propria

T1 Tumor invades submucosa

T2 Tumor invades muscularis propria

T3 Tumor invades through the muscularis propria into pericolorectal tissues

T4a Tumor penetrates to the surface of the visceral peritoneum

T4b Tumor directly invades or is adherent to other organs or structures

Regional Lymph Nodes (N)

Nx Regional lymph nodes cannot be assessed

N0 No regional lymph nodes

N1 Metastasis in 1-3 regional lymph nodes

N1a Metastasis in one regional lymph node

N1b Metastasis in 2-3 regional lymph nodes

N1c Tumor deposit(s) in the subserosa, mesentery, or non peritonealized pericolic or perirectal tissues without regional nodal metastasis

N2 Metastasis in 4 or more regional lymph nodes

N2a Metastasis in 4-6 regional lymph nodes

N2b Metastasis in 7 or more regional lymph nodes

T2-weighted imaging was the most important imaging sequences. The tumor signal as compared to muscularis propria and the submucosa were recorded. The signal was recorded as isointense or hyperintense. All malignant lesions picked up were evaluated for involvement of submucosa, muscularis and serosal breach.

Imaging criteria used for serosal breach and extraserosal extension into pararectal fat included:

- 1) Focal contour abnormalities of the serosa including spiculations, angulations and bulging.
- 2) Well defined nodular lesion with mild contour irregularity which represents tumor extension out of an involved lymph node.
- 3) Linear tumor streaks into pararectal fat which represents lymphatic invasion.
- 4) Ill-defined nodular lesion having irregular margins suggesting venous spread.

ADC values were individually calculated for each sextant by placing 3 small circular ROIs of 0.20 mm² area in area of restriction. An average ADC was then calculated.

STATISTICAL ANALYSIS

All qualitative variables were described in terms of frequency and proportion. All quantitative variables were estimated using measures of central location (mean, median). The sensitivity, specificity, accuracy, positive predictive value and negative predictive values were calculated.

RESULTS

In the present study, out of 64 patients 39 were males and 25 were females. Male to female ratio was 1.56:1. Most of the patients (59.37%) were in 5th to 6th decade of life. MRI was performed and patients were evaluated for the involvement of submucosa, muscularis and serosal breach [Table/Fig-1-12].

Histopathological Types: Adenocarcinoma accounted for 88.70% of all rectal tumors [Table/Fig-1]. The most

Histopathological Type	Number of Patients
Moderately differentiated Adenocarcinoma	36
Papillary Adenocarcinoma	4
Mucinous Adenocarcinoma	10
Poorly differentiated Adenocarcinoma	5
GIST	3
Tubovillous Adenoma	1
Malignant Melanoma	1
Non Keratinising Squamous Cell Carcinoma	1
Adenocarcinoma of Anal Canal	1
Total	62

[Table/Fig-1]: Different histopathological types of rectal tumors.

common histopathological type was moderately differentiated adenocarcinoma (58%). The second most common was mucinous adenocarcinoma (16%).

MRI Morphology of different Rectal Tumors: Sometimes a smaller biopsy specimen may not be adequate for

Type of Tumor	T2WI	T1WI	Diffusion	ADC (Avg.)	Comments
GIST [Table/Fig-4]	Heterogeneous	Diffusely hypo-intense	Shows restriction	Drop in signal (0.8)	Well defined, submucosal mass
Malignant Melanoma [Table/Fig-5]	Hypo-intense	Hyper-intense	May or may not show restriction	(0.66)	Anorectal junction mass, early hemorrhagic metastasis
Mucinous adenocarcinoma [Table/Fig-6&7]	Hyper-intense	Isointense	Shows restriction	T2 shine through (1.10)	Diffuse involvement with early spread
Others	Intermediate	Hypo-intense	May or may not show restriction	(0.85)	Variable appearance

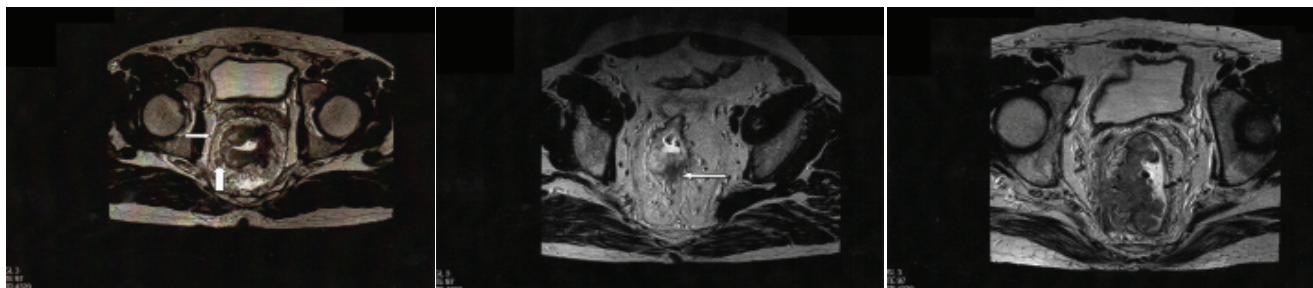
[Table/Fig-2]: MRI morphology of different rectal tumors.

histopathological grading of the rectal tumor. In such a scenario important morphological features on the MRI may be helpful. However, it is not possible by MRI to differentiate all tumors but some tumors show specific MRI appearance as shown in [Table/Fig-2]. The pTNM staging and MRI staging comparison has been depicted in [Table/Fig-9,11]. Out of 36 operated patients one patient was over staged as stage T2 and 3 patients were over staged as T3 tumor [Table/Fig-10].

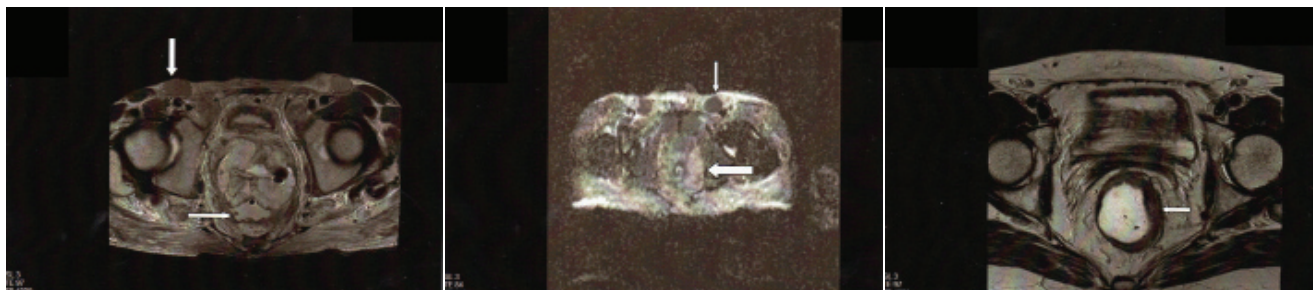
Out of 36 operated patients, 18 showed evidence of lymph node metastasis on histology.

DISCUSSION

Peak incidence for colorectal carcinoma is between ages 60 and 79 [4]. In our study male: female ratio was 1.56:1. The youngest patient was 24 years old and the oldest was 80 year old, with mean age being 57 years. Most of the patients (59.37%) were in 5th to 6th decade of life. Adenocarcinoma accounted for 88.70% of all rectal tumors. Several studies have suggested the use of rectal cleansing and rectal distension by various materials to prevent image misinterpretation due to stool residues. However, distension of rectal lumen is controversial [5]. Brown et al., found optimal results without rectal luminal distension [6]. In the present study rectal distension was not performed and no intravenous/rectal contrast agent was used. Double contrast MRI method



[Table/Fig-3]: T2 weighted axial image in a case of carcinoma rectum showing a tumor nodule (thick arrow) adjacent to mesorectal fascia (thin arrow) suggestive of positive CRM. **[Table/Fig-4]:** T2 weighted axial image showing Stage T3 tumor. Note the linear streaking in the pararectal fat suggestive of infiltration. **[Table/Fig-5]:** T2 weighted axial image showing Stage T4 disease with positive circumferential resection margin. (Images from left to right)



[Table/Fig-6]: T2 weighted axial image in a case of mucinous adenocarcinoma of rectum 2 month after chemotherapy. Note the mucin lakes (thin arrow) and bulky inguinal lymphadenopathy (thick arrow). **[Table/Fig-7]:** ADC image of mucinous adenocarcinoma of rectum. Note the T2 shine through effect of the tumor (thick arrow) however the inguinal nodes (thin arrow) show restriction. **[Table/Fig-8]:** T2 weighted axial image showing Stage T2 mass involving the upper rectum with intrarectal Ultrasound gel as a distending agent, this gives better delineation of small masses (arrow). (Images from left to right)

MRI "T" Staging	Pathological "T" Staging				
	T1	T2	T3	T4	Total
T1	1	0	0	0	1
T2	1	12	0	0	13
T3	0	3	16	0	19
T4	0	0	0	3	3
Total	2	15	16	3	36

[Table/Fig-9]: Showing pathological 'T' staging and MRI 'T' staging comparison.

Staging	True positive	True negative	False positive	False negative	Accuracy	Sensitivity	Specificity	PPV	NPV
T1	1	34	0	1	97.22	50	100	100	97.14
T2	12	20	1	3	94.11	80	95.23	92.3	86.95
T3	16	17	3	0	91.66	100	85	84.21	100
T4	3	33	0	0	100	100	100	100	100
Average	-	-	-	-	95.75	82.5	95.05	94.12	96.02

[Table/Fig-10]: Showing the statistical comparison of T staging.

MRI "N" Staging	Pathological "N" Staging			Total
	N0	N1	N2	
N0	7	0	0	7
N1	9	9	0	18
N2	2	1	8	11
Total	18	10	8	36

[Table/Fig-11]: Showing pathological 'N' staging and MRI 'N' staging comparison.

Staging	True positive	True negative	False positive	False negative	Accuracy	Sensitivity	Specificity	PPV	NPV
N0	7	18	0	11	69.44	33.88	100	100	62.06
N1	9	17	9	1	72.22	90	65.38	50	94.44
N2	8	25	3	0	91.66	100	89.28	72.72	89.28
Average	-	-	-	-	77.77	74.62	84.88	74.24	81.92

[Table/Fig-12]: Showing the statistical comparison of N staging.

employs use of ferristene-based super-magnetic contrast medium for luminal distension of rectum in conjunction with intravenous gadolinium enhanced MRI. This double contrast MRI method results in sensitivity of 100%, specificity of 90% and accuracy of 90% for distinguishing tumor stages [7]. Several studies have suggested contrast enhanced T1-weighted sequences are not effective for local staging of rectal cancer. However, Beets-tan et al., [8] reported the potential advantage of contrast enhanced thin section MRI with a phased array coil in differentiation of reactive changes from true tumor invasion. They also reported that MRI could not be used to reliably distinguish between fibrosis with and without tumor cells.

Beets-Tan et al., [8] reported that the overall accuracy for 'T' stage prediction with phased array MRI varies between 67% and 83%. In our study the overall accuracy of phased

array MRI for 'T' staging of rectal cancer was 95.75%. The accuracies were 97.22% for T1 tumor, 94.11% for T2 tumor, 91.66% for T3 tumor and 100% for T4 tumor. There are many reasons for this wide range in accuracies. The submucosal layer of rectal wall is not well visualized on phased array MRI unless there is edema. Therefore, it is very difficult to distinguish between a T1 tumor (limited to submucosa) and T2 tumor (outgrowing the submucosa and invading muscular bowel wall). There is also difficulty in differentiating T2 and borderline T3 tumor (with desmoplastic reaction). Desmoplastic reactions in front of a tumor that is free from tumor nests (pT2) cannot be discriminated from desmoplastic reactions that do contain tumor nests (pT3). It is often better to overstage a pT2 tumor as T3 than to understage. In our study the accuracy to diagnose T2 lesion was 94.11% sensitivity was 80%, specificity was 95.23%, positive predictive value

was 92.30% and negative predictive value was 86.95%. MRI can select tumors limited to bowel wall (pT1-T2) with high sensitivity. Dresen RC et al., reported that when bowel wall on T2-weighted MR images can be seen as intact hypointense line around the tumor, then tumor is confined to bowel wall with high positive predictive value (86-91%) [9]. In our study large T3 and T4 tumors can accurately be identified with MRI with sensitivity of 100%. Specificity was 80% and 100% for T3 and T4 tumor respectively.

CRM involvement is predicted when a tumor extends to within 1mm of mesorectal fascia on MRI. A large multicentric study (Mercury study group) in 2006 reported an overall accuracy of 88%, positive predictive value of 54% and negative predictive value of 94% for MRI prediction of CRM involvement. In our study only 3 cases of mesorectal fascia invasion were operated in which MRI was 100% accurate in diagnosing mesorectal fascia invasion. The small number of patients had a negative effect on the general preoperative tumor staging purpose of the study. Because of few number of T4 lesions operated, we were unable to assess the real accuracy of MRI for the detection of mesorectal fascia involvement. However, this study and the study conducted by Beets-Tan et al., [8] and Branagan et al., [10] shows that MRI can predict patients in whom the CRM is not involved. This enables surgeon to proceed to surgery without the need for preoperative radiotherapy.

In rectal cancer metastasis the lymph nodes are frequently small (<5mm), hence the use of size criteria in rectal cancer nodes is limited. When applying size as the only criteria, small metastatic nodes are thus under staged while over staging occurs in the larger size nodes. Morphological criteria in addition to size improve the nodal evaluation. Nodes showing heterogeneous signal and irregular border pattern are more likely to be involved, while nodes that are homogenous in signal and sharply delineated often prove to be benign. With the use of these criteria for nodal staging, we found overall accuracy of 77.77%, sensitivity of 74.62% and specificity of 84.88%. Ultra Small Super Paramagnetic Iron Oxide (USPIO) enhanced MRI is used for differentiation between benign and malignant lymph nodes. Benign lymph nodes take up USPIO and shows decrease signal on T2 weighted MRI, owing to susceptibility artifacts. Malignant lymph nodes show no decrease in signal due to replacement of macrophages by tumor cells [11]. Drawbacks of USPIO are inability to detect lymph node micro-metastasis (< 1mm in size). Certain benign condition like fatty hilum and focal nodular fibrosis do not show decrease in signal on USPIO enhanced MRI resulting in false positive diagnosis of metastasis.

Rectal cancer may exhibit either restricted or increased diffusion, depending on its cellular architecture. Restricted

diffusion in high cellular density and increased diffusion in necrosis, intratumoral edema and cystic component. ADC measurement appears to be predictive of tumor response to chemotherapy and radiation treatment. Early increase in ADC values after commencing treatment was predictive of better treatment outcome [12].

Moving table MRI for simultaneous assessment of metastatic spread: Sliding Multislice (SMS) is an interleaved multislice acquisition technique for axial Continuously Moving Table (CMT) imaging [13]. SMS was implemented as moving table scan to assess potential metastatic spread from rectal cancer. Major benefits of this new technology are seamless imaging within minutes of acquiring two different MR contrasts. SMS moving table MRI has inferior lesion characterization compared to standard MRI technique, however in near future with implementation of additional image contrast and continual technical optimization, image quality will be comparable to conventional stationary imaging protocol. This will dramatically improve diagnosis and treatment of rectal cancer patients.

Advanced MRI technique includes use of an endorectal coil (endorectal MRI). It allows differentiation of bowel wall layers and thus permits more accurate 'T' stage determination. Endorectal MRI cannot be performed in severely stenotic infiltrating lesions. It cannot assess the mesorectal fascia and CRM adequately [14,15].

Other advances in staging rectal cancer include Positron Emission Tomography (PET)/CT colonography which provide both functional and anatomical information [16,17]. Rectal cancer shows higher blood flow (BF) and shorter Mean Transit Time (MTT) compared to normal rectum on CT/MR perfusion studies [18,19].

The cost of latest magnet and the problems associated with use of endorectal coils are prohibitive especially at smaller centers. Most centers in India use a 1.5 Tesla (T) MR scanner and the use of endorectal coil has not yet found much acceptance. In such a scenario, we have undertaken this study to review the feasibility of using MRI at 1.5T as a staging modality for rectal cancer.

LIMITATIONS

Main limitation of our study was the small number of patients. The number of T2 lesions was low. Only one T1 lesion and three T4 lesions were operated. We were unable to assess the real accuracy of MRI for detection of mesorectal fascia involvement as only few number of T4 lesion cases underwent operation.

CONCLUSION

MRI is currently the imaging modality of choice for accurate evaluation of mesorectal fascia and lateral tumor extent and thus makes accurate prediction about CRM. It is possible to

avoid overtreatment or under treatment of carcinoma rectum with the help of MRI as we can appropriately select patients for neoadjuvant chemo-radiotherapy / primary surgery.

REFERENCES

- [1] Goligher JC (ed) Surgical anatomy and physiology of the colon, rectum, and anus. In: Surgery of the anus, Rectum, and Colon, 2nd edn. Bailliere, Tindall & Cassel, London. 1967. pp 1-54.
- [2] Bisset IP, Chau KY, Hill GL. Extrafascial excision of the rectum: surgical anatomy of the fascia propria. *Dis Colon Rectum*. 2000;43(7):903-10.
- [3] Berlin JW, Gore RM, Yaghamai V, Newmark GM, Miller FH. Staging of colorectal cancer. *Seminars in Roentgenology*. 2000;35(4):370-84.
- [4] Jemal A, Thomas A, Murray T and Thun M. Cancer Statistics, 2002. *CA Cancer J Clin*. 2002; 52(1):23-47.
- [5] Iafrate F, Laghi A, Paolantonio P, Rengo M, Mercantini P, Ferri M, et al. Preoperative staging of rectal cancer with MR Imaging: correlation with surgical and histopathologic findings. *RadioGraphics*. 2006;26:3(3):701-14.
- [6] Brown G, Daniels IR, Richardson C, Revell P, Peppercorn D, Bourne M. Techniques and trouble-shooting in high spatial resolution thin slice MRI for rectal cancer. *Br J Radiol*. 2005; 78:245-51.
- [7] Wallengren NO, Holtas S, Andren-Sandberg A, Jonsson E, Kristoffersson DT, and McGill S. Rectal carcinoma: double-contrast MR imaging for preoperative staging. *Radiology*. 2000;215(1):108-14.
- [8] Beets-Tan RG, Beets GL, Vliegen RF, Kessels AG, Van Boven H, De Bruine A, et al. Accuracy of magnetic resonance imaging in prediction of tumor-free resection margin in rectal cancer surgery. *Lancet*. 2001;357(9255):497-504.
- [9] Dresen RC, Beets GL, Rutten HJ, Englene SM, Lahaye MJ, Vliegen RFA, et al. Locally advanced rectal cancer: MR imaging for restaging after neoadjuvant radiation therapy with concomitant chemotherapy part I. Are we able to predict tumor confined to the rectal wall? *Radiology*. 2009;252:71-80.
- [10] Branagan G, Chave H, Fuller C, McGee S, Finnis D. Can magnetic resonance imaging predict circumferential margins and TNM stage in rectal cancer? *Dis Colon Rectum*. 2004;47:1317.
- [11] Lahaye MJ, Engelen SM, Kessels AG, de Bruine AP, von Meyenfeldt MF, van Engelshoven JM, et al. USPIO-enhanced MR imaging for nodal staging in patients with primary rectal cancer: predictive criteria. *Radiology*. 2008;246(3):804-11
- [12] Sauer R, Becker H, Hohenberger W, Rödel C, Wittekind C, Fietkau R, et al. Preoperative versus postoperative chemoradiotherapy for rectal cancer. *N Engl J Med*. 2004;351(17):1731-40.
- [13] Fautz Hp, Kannengiesser SA. Sliding Multislice (SMS): a technique for minimum FOV usage in axial continuously moving-table acquisitions. *Magn Reson Med*. 2006;55(2):363-70.
- [14] Hunerbein M, Pegios W, Rau B, Vogl TJ, Felix R, Schlag PM. Prospective comparison of endorectal ultrasound, three dimensional endorectal ultrasound and endorectal MRI in the preoperative evaluation of rectal tumors. Preliminary results. *Surg Endosc*. 2000;14(11):1005-09.
- [15] Kim NK, Kim MJ, Yun SH, Sohn SK, Min JS. Comparative study of transrectal ultrasonography, pelvic computerized tomography and magnetic resonance imaging in preoperative staging of rectal cancer. *Dis Colon Rectum*. 1999;42(6):770-75.
- [16] Kinner S, Antoch G, Bockisch A, Veit-Haibach P. Whole-body PET/CT colonography: a possible new concept for colorectal cancer staging. *Abdom Imaging*. 2007;32(5):606-12.
- [17] Gollub MJ, Akhurst T, Markowitz AJ, Weiser MR, Guillem JG, Smith LM, et al. Combined CT colonography and 18F-FDG PET of colon polyps: potential technique for selective detection of cancer and precancerous lesions. *AJR Am J Roentgenol*. 2007;188(1):130-38.
- [18] Sahani DV, Kalva SP, Hamberg LM, Hahn PF, Willett CG, Saini S, et al. Assessing tumor perfusion and treatment response in rectal cancer with multisection CT: initial observations. *Radiology*. 2005;234(3):785-92.
- [19] Bellomi M, Petralia G, Sonzogni A, Zampino MG, Rocca A. CT perfusion for the monitoring of neoadjuvant chemotherapy and radiation therapy in rectal carcinoma: initial experience. *Radiology*. 2007;244(2):486-93.

AUTHOR(S):

1. Dr. Sitaram Barath
2. Dr. Jeevan A Vernekar
3. Dr. Sachin Shashikant Amate

PARTICULARS OF CONTRIBUTORS:

1. Ex. Senior Resident, Department of Radiology, Goa Medical College, Bambolim, Goa, India.
2. Professor and Head, Department of Radiology, Goa Medical College, Bambolim, Goa, India.
3. Junior Resident, Department of Radiology, Goa Medical College, Bambolim, Goa, India.

NAME, ADDRESS, E-MAIL ID OF THE CORRESPONDING AUTHOR:

Dr. Jeevan A Vernekar,
Professor and Head, Department of Radiology, Goa Medical College, Bambolim, Goa-403202, India.
E-mail: jeevanvernekar11@gmail.com

FINANCIAL OR OTHER COMPETING INTERESTS:

None.

Date of Publishing: **Apr 01, 2017**